

The TMJ is the “Master Link”

I have been practicing Equine Sports Medicine for 17 years and in the last decade I have seen the horse market flooded with supplements, blankets, lasers and various devices for physical therapy. I am shocked at the influx of equine medications manufactured for gastric ulcers, neurologic diseases and inflammatory conditions. Why are our horses so out of balance and so in need of all these medications? Is it environmental pressure, the increased amount of travel to shows and events throughout the US and Internationally? All of these things can add to the picture but I believe many horsemen and women (the veterinary community included) are unaware of the importance of the TMJ to a horse's balance, digestion, biomechanics and overall well being. I consider this the “Master Link.” Restore this master link to optimal wellness and many of the other psychological and physical issues, internal organ imbalances and body compensations simply disappear.

The Temporomandibular Joint (TMJ) is critical for a horse's survival and well being. It has two primary functions, mastication or the grinding of food and balance, i.e. its relationship with the ground or posture. With a balanced jaw a horse's body can achieve a state of self perpetuating wellness, everything from digestion to cell regeneration and rapid healing occurs easily, naturally.

ANATOMY: The TMJ connects the temporal bone which expands across the horse's forehead to the mandible, which is the lower portion of the skull. It actually consists of two parts, an upper sliding joint and the lower hinge joint. An articular disc separates the two compartments and the entire joint is encapsulated and contains synovial fluid. It is a very tight joint, reinforced by tendons, ligaments and supported by an intricate array of muscles.

Many horses suffer from temporomandibular joint pain(TMJ) which is articular and perhaps even more insidious is a condition called temporomandibular dysfunction.(TMD) This involves more soft tissue pain; myofascial and

ligamentous. These horses' adapt as the inflammatory process slowly progresses, what starts as a bit of discomfort becomes a raging headache. Once you have knowledge of what to look for, you will be able to recognize it, the evaluation is more subtle than just looking to see if they need their teeth floated.

Evaluating for TMJ Pain or TMD:

1. Observation: Watch your horse chewing. Look for symmetry or balance side to side. Does he swing his jaw to both sides? Does he hold his head with a tilt while he eats? Is he dropping food? Does he leave the stems of hay? Observe his head when he is not eating and look straight at him face to face. Are the ears, eyes and nostrils even or asymmetric? How about the bony prominence of the jaw joint or the facial crest that runs down the side of the head? Is one more prominent than the other? This is a good time to evaluate the forehead or temporalis muscle and the cheek or masseter muscle for symmetry also. The pterygoid muscle is equally important but less noticeable on visual inspection.
2. Incisor Evaluation: The incisor pattern, length and angle directly affect the biomechanics of the TMJ. Look straight at your horse's incisors; they should be aligned top to bottom. There is pathology in the mouth and TMJ if they are off center or there is a wedge sending them one direction and not the other.(figure 1) Now look from the side is there an overbite or an overjet which is really an incomplete overbite? (figure 2) If so chances are your horse cannot put his head down and drop his mandible into a comfortable or neutral position because anterior motion of his jaw is impeded. Check for anterior and posterior motion visually or by gently placing your finger at the incisor occlusal line(where the front teeth meet). When the head is raised normal posterior motion should pull the lower incisors slightly back. When you lower the horses head the lower incisors should move forward if they have healthy anterior motion of the jaw. The lack of anterior/posterior motion indicates the biomechanics of the jaw can be improved.

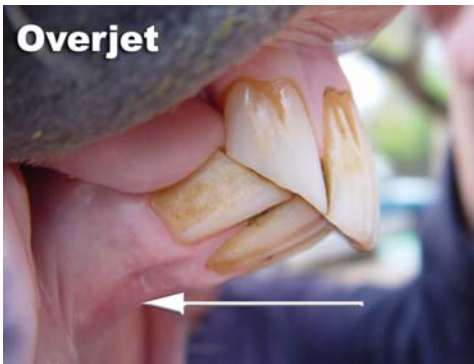

Figure 1

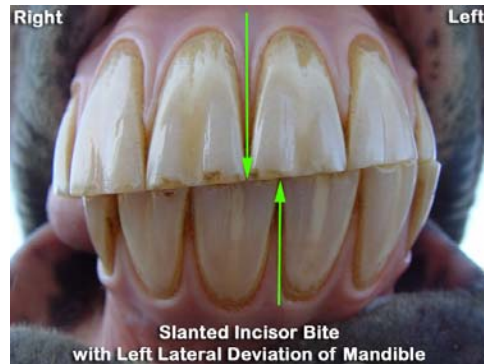


Figure 2

3. Listen: There is a harmonic resonance in a healthy jaw that one can hear. Listen to your horse grazing or eating hay with his head down. All horses should be fed at ground level. With their head down the atlanto-axial joint opens (C1-C2), the mandible comes down and forward, the upper and lower cheek teeth meet at the optimal occlusion and the muscles and soft tissues in the head and neck go into the perfect balance of tension and relaxation for proper chewing and neurological input. Wild horses graze for 15-20 hours a day. All of the wild horse skulls I've found have nearly perfect incisor and molar patterns. When you listen to your horse chewing there should be a clear, clean sound if everything is healthy. It is a resonance, which is also a frequency or vibration that is like a lullaby to the nervous system. Squeaks, or pops or clicking sounds could indicate TMJ or dental pathology.
4. Gentle palpation of the TMJ joint space can indicate asymmetry or pain. One side may feel shallow and open while the other side might feel tight and pinched. Palpation and observation of the muscle on the forehead, the cheek muscle and the pterygoid muscle which is difficult to observe but can be palpated on the medial aspect of the mandible.
5. Palpation of acupoints- TH17, ST7, Bao-Sai, the facial crest trigger points and the medial pterygoid muscle attachment- (see figure 3) for those familiar with acupuncture or acupressure.

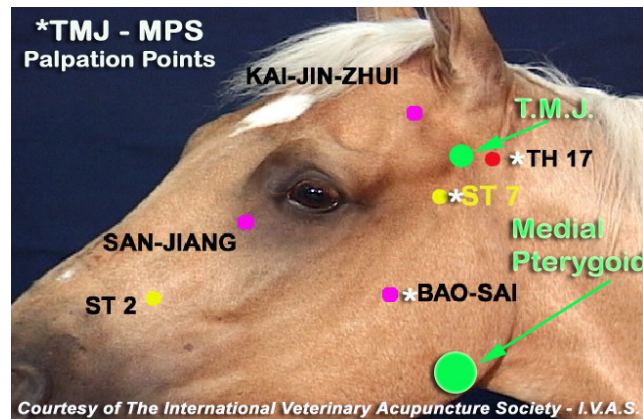


Figure 3

After doing the above evaluation if you suspect your horse has some TMJ dysfunction, please have a vet or a qualified equine dentist perform an exam with a full mouth speculum. Many problems in the rear molars cannot be assessed without one. Just be sure the examiner does not keep the speculum on longer than necessary and opens it only as wide as necessary.

I am an advocate and teacher of **TMJ Awareness Dentistry**. This is a holistic approach to dentistry. I feel equine dentistry has advanced too far toward the comfort of the dentist and less toward the comfort and safety of the horse. The overuse of power dental instruments is the primary reason I see and treat so many TMD horses. Although a true artist can do the work correctly with power instruments, it is so easy to over float with them. I have found that a more accurate balance can be achieved with hand instruments. If I find extreme pathology I will use my power instruments judiciously, but I always finish with hand instruments.

My colleagues and I use hand instruments that are ergonomically correct, specifically designed for a horse's mouth. We use minimal sedation, and are willing to add more if necessary. However, our goal is to have the horse as aware as possible to the subtle changes that are occurring to his nervous system as we make adjustments to the teeth. This kind of **TMJ Awareness Dentistry** is really adjusting the "gyroscope" and is often my first step in treating neurologic diseases.

We have found that many power floaters take off too much clinical crown, as well as they often obliterate the horse's natural molar table angles. Larger amounts of sedation are required to allow these instruments into the oral cavity, then the head is hoisted or tied up into a very unnatural position. Power floating can be so excessive that it decreases the surface contact between molars that a horse would naturally have. This leads to severe myofascial pain syndrome (TMD) because the horse wants to get contact between his molars so he clinches his jaw and constantly compresses his muscles tendons and ligaments to try to get that contact. Sometimes it takes years for that clinical crown to come back. Molar table angles and surface contact is crucial to the guidance that relates to the biomechanics of chewing as well as posture, balance, and equilibrium.

The bottom line is, I believe power tools have allowed dentists to become overly aggressive in equine dentistry and with one quick head shake the proper table angles can be altered. Many dentists are more concerned with eliminating sharp edges than restoring the proper biomechanics to the jaw joint. Often practitioners float the molars and either leave the incisors untouched or follow up with adjusting the incisors to fit the work that was done on the molars. **TMJ awareness dentists** start with a thorough examination of the head, hyoid, poll and whole body for asymmetries and symptoms of TMD. We address the incisors first. The length, angle, and balance of the incisor tables are directly related to the TMJ. Sometimes incisor pathology can only be reduced in increments while the horse adjusts to the new TMJ alignment. Some pathology should not be corrected, especially in aged horses that have been compensating for years and have adapted, in these cases one does minimal work mostly to allow more comfort and maximum surface to surface contact between the teeth.

Once optimum incisor alignment has been achieved we then put the speculum on and move to the molar tables. Remember we want the horse's participation and integration during the process and we don't hoist their head up with a hydraulic head lift or tie them to an overhead beam. It is easy to create inappropriate changes to the molar table angles with the head held high and the

neck hyper extended. We are willing to kneel on knee pads so that we do the work with the horses head in a natural position, i.e. the place were the horse spends most its time eating or being ridden. (Figure 4) We leave as much clinical crown and table surface as possible on the molars and pay close attention to table angles. This is critically important in the rear most molars as they are closest to the TMJ, brain, and central nervous system. Their occlusal surface and angle is critical to proper guidance, body biomechanics and balance. We always complete our dentistry with some stretching, myofascial and trigger point release work, essential oils, homeopathy and sometimes chiropractic and acupuncture.



Figure 4

Even with the best of dental care, it takes a total holistic approach to completely treat TMD issues. Dental work alone is a very important starting point, but it will not completely resolve many TMJ/TMD issues. This problem is often slow and insidious in its occurrence; it does not happen over night. We often pull

in the help of cranio-sacral therapists, body workers who do extensive soft tissue work, farriers to properly balance the feet, we use cyma therapy, micro-current, laser, chiropractic, acupuncture, homeopathy, bit changes, saddle changes, oral or injectable chondro protective agents and sometimes anti inflammatory to get the horse back to total balance and wellness.

I urge you to take a close look at your horses TMJ functioning. It can be easily overlooked. As I said earlier in this article I consider it the “Master Link” in the chain of healthy equine biomechanics and movement. I see far too many hocks and backs get injected that actually have TMD; although there will often be some temporary improvement especially if corticosteroids are used, after a while the imbalance shows up somewhere else, often the feet or neck. Unkink the master link and be sure the feet are balanced and you will see the life force flow through your horse’s entire body. You may still have body work to do and old postural compensations to correct, but it is much more possible for the horse to achieve a state of self perpetrating wellness, vitality, and strength with a healthy happy TMJ. This is homeostasis, every cell in the body has a built in intelligence to allow well being, it is natural and it is where they want and need to be.

MORE DETAIL ON TMJ Function & its RELATION TO THE WHOLE HORSE

A) Mastication and Digestion: Chewing the food properly is the very first step in healthy digestion. A horse must be able to move his jaw from side to side (lateral excursion), forward and back (anterior/posterior movement) and up and down to reinforce the grind in order to chew food properly. When dysfunction occurs a horse will make many adaptations in order to survive, but these changes trickle back into the entire body. We have all heard the old adage “no hoof no horse,” the same goes for the teeth. Without the ability to chew and digest food, chances for survival are slim.

B) Neurology and Balance: The jaw joint is highly innervated and surrounded by structures that dictate the horse’s balance and equilibrium. It is anatomically the closest joint in a horse’s body to the brain and brainstem. Its proprioceptors tell the horse where he is in space, or what his posture is, where

his right leg is placed in that sliding stop, over that jump or on that rocky uneven trail. The neurology is intricate and beyond the scope of this article, but be aware that the hyoid and cranial nerves are intricately connected with the jaw. The hyoid apparatus in the throatlatch is a group of 10 bones that give biomechanical form and function to the larynx, pharynx and the tongue. Changes in dental occlusion lead to stimulation of the periodontal ligaments or lack of in the case of over floating. These ligaments sense tooth strike and stimulate afferent nerve input through the trigeminal nerve (one of the 5 cranial nerves involved with the TMJ). All of this is an intricate web of information weaving the biomechanics and neurology of the jaw together.

C) More Neurology: The TMJ is part of the stomatognathic system, a neurological system that governs balance and equilibrium. All components of the system are from the shoulder forward. "Where the head goes the body goes." This includes the eyes, hyoid apparatus, proprioceptors and dural connections from the cervical spine which connect all the way to the sacrum and pelvis. Changes in the muscle tone in the head and neck increase dural tension all the way to the sacrum. This is why we often see a reciprocal pattern in the pelvis and sacrum to changes in the TMJ and pathology in the incisors.

D) Acupuncture Channels Convergence Point: There is another system of vitality and connection in the body known as the acupuncture meridians or channels. Vital life force or Chi flows along these channels and maintain health when it is harmonious. If it is blocked or altered in any way it can create dis-ease or dysfunction in the body. Six different acupuncture channels converge on or very close to the TMJ. Three travel to the front legs LI, SI, and TH, and three to the hind legs GB, ST, and BL. This is another way to explain how the hind legs pelvis and sacrum can be adversely affected by TMJ or TMD.

Dr. Heather K. Mack

www.balancedequinewellness.com

Mobile: 760-447-0776

